

Smartphone Integration of Artificial Intelligence for Automated Plagiocephaly Diagnosis

Ayden Watt, MSc*

James Lee, MD, MSc†

Matthew Toews, PhD, MEng‡

Mirko S. Gilardino, MD, MSc,
FRCS, FACS†

Background: Positional plagiocephaly is a pediatric condition with important cosmetic implications affecting ~40% of infants under 12 months of age. Early diagnosis and treatment initiation is imperative in achieving satisfactory outcomes; improved diagnostic modalities are needed to support this goal. This study aimed to determine whether a smartphone-based artificial intelligence tool could diagnose positional plagiocephaly.

Methods: A prospective validation study was conducted at a large tertiary care center with two recruitment sites: (1) newborn nursery, (2) pediatric craniofacial surgery clinic. Eligible children were aged 0–12 months with no history of hydrocephalus, intracranial tumors, intracranial hemorrhage, intracranial hardware, or prior craniofacial surgery. Successful artificial intelligence diagnosis required identification of the presence and severity of positional plagiocephaly.

Results: A total of 89 infants were prospectively enrolled from the craniofacial surgery clinic (n = 25, 17 male infants [68%], eight female infants [32%], mean age 8.44 months) and newborn nursery (n = 64, 29 male infants [45%], 25 female infants [39%], mean age 0 months). The model obtained a diagnostic accuracy of 85.39% compared with a standard clinical examination with a disease prevalence of 48%. Sensitivity was 87.50% [95% CI, 75.94–98.42] with a specificity of 83.67% [95% CI, 72.35–94.99]. Precision was 81.40%, while likelihood ratios (positive and negative) were 5.36 and 0.15, respectively. The F1-score was 84.34%.

Conclusions: The smartphone-based artificial intelligence algorithm accurately diagnosed positional plagiocephaly in a clinical environment. This technology may provide value by helping guide specialist consultation and enabling longitudinal quantitative monitoring of cranial shape. (*Plast Reconstr Surg Glob Open* 2023; 11:e4985; doi: 10.1097/GOX.0000000000004985; Published online 15 May 2023.)

INTRODUCTION

Positional plagiocephaly is a common pediatric condition, representing a large proportion of the referrals to craniofacial clinics in recent years.¹ Since the introduction of the American Association of Pediatrics' Back to Sleep campaign in the 1990s, we have seen a dramatic reduction in sudden infant death syndrome. However, this shift was balanced by a notable increase in the frequency of

deformational plagiocephaly caused by prolonged external pressure to the back of the infant's head when put to sleep.^{2–6} Although this trade-off is, without question, the preferred option, the increase in prevalence of positional plagiocephaly to almost 40% has bolstered research efforts into long-term sequelae, neurological implications, and clinical outcomes of the diagnosis.^{7,8} Importantly, deformational plagiocephaly has been found not to imply any additional risk of neurodevelopmental deficits, presenting as a primarily aesthetic pathology with long-term psychological implications from bullying if the condition is left untreated.^{9,10}

In tangent with research into the clinical outcomes of positional plagiocephaly, researchers began looking for ways to optimize treatment protocols and facilitate earlier diagnosis. In a previous study, the authors demonstrated

From the *Department of Experimental Surgery, McGill University, Montreal, Canada; †Division of Plastic and Reconstructive Surgery, McGill University Health Center, Montreal, Canada; and ‡École de Technologie Supérieure, Department of Systems Engineering, Montréal, Canada.

Received for publication January 24, 2023; accepted March 17, 2023.

Copyright © 2023 The Authors. Published by Wolters Kluwer Health, Inc. on behalf of The American Society of Plastic Surgeons. This is an open-access article distributed under the terms of the [Creative Commons Attribution-Non Commercial-No Derivatives License 4.0 \(CCBY-NC-ND\)](https://creativecommons.org/licenses/by-nc-nd/4.0/), where it is permissible to download and share the work provided it is properly cited. The work cannot be changed in any way or used commercially without permission from the journal.

DOI: 10.1097/GOX.0000000000004985

Disclosure statements are at the end of this article, following the correspondence information.

Related Digital Media are available in the full-text version of the article on www.PRSGlobalOpen.com.

that earlier diagnosis is associated with better aesthetic outcomes, shorter treatment times, lower costs for treatment, a lower stress burden for parents, and lower costs for the healthcare system overall.¹¹ In large part, this is due to early detection maximizing the chance of successful intervention with repositioning and physical therapy, negating the need to progress to helmet therapy or, in extreme cases, surgery.¹¹ It is not surprising then that various techniques have been developed to accurately and efficiently diagnose head deformities in the pediatric population.¹² Although a number of studies have reported strong diagnostic performances for their respective tools, the majority were plagued by design limitations requiring centralization at specialized centers or high cost barriers, which inhibit widespread adoption.¹² Given the current standard for diagnosis of deformational plagiocephaly remains visual assessment of the cranial form by a craniofacial specialist, artificial intelligence (AI) systems present a promising method for objectively quantifying a predominantly subjective diagnosis. In turn, such a companion tool may provide physicians the necessary means to make more informed clinical decisions.

In consideration of this context, the objective of this study was to conduct the first larger-scale prospective study of a newly developed AI tool that allows the quantitative evaluation and diagnosis of an infant's cranium, and to compare these AI-sourced diagnoses to a standard clinical evaluator.

METHODS

Study Design and Patient Population

This study was approved by the appropriate institutional review board (McGill University Health Center IRB 2021-6964). A total of 134 infants between the ages of 0 and 12 months were prospectively recruited from two sites, either the newborn nursery of a major urban hospital ($n = 107$) or the outpatient craniofacial surgery clinic at a major children's hospital ($n = 27$), between November 2021 and February 2022 (Fig. 1). Exclusion criteria for the study included infants presenting with hydrocephalus, intracranial tumors, intracranial hemorrhage, hardware (eg, shunts), suspected craniosynostosis, or prior craniofacial surgery.

This study was conducted in accordance with applicable legislation and the Tri-Council Policy Statement: Ethical Conduct for Research Involving Humans (2018), as well as in respect of the requirements set out in the applicable standard operation procedures of the research institute and the recommendations of the institutional ethics committee. Reporting of this study was done in accordance with the Standards for Reporting Diagnostic Accuracy Studies guidelines.¹³

Data Acquisition and Analysis

At the time of recruitment, a single 3-second video of the infants' head taken from a top-down perspective was recorded for all subjects, along with their age and sex. Additionally, a clinical evaluation of head shape and relevant

Takeaways

Question: Can a smartphone-based artificial intelligence software detect clinically significant positional plagiocephaly?

Findings: In this prospective diagnostic validation study that included 89 infants (<12 months old), the artificial intelligence algorithm being evaluated achieved a diagnostic accuracy of 85.39% with a sensitivity of 87.50% and a specificity of 83.67% when compared with a standard clinical examination.

Meaning: Performant artificial intelligence tools could be a valuable resource for identification, quantification, and monitoring of positional plagiocephaly.

clinical history was recorded as perceived by the physician of record [one of several participating pediatricians in the nursery, and a pediatric craniofacial surgeon (M.G.) at the outpatient craniofacial clinic]. The total time required to use the application was noted during data collection. Due to the significant differences in development between newborn (<48 hours) and older (3–12 months) infants, the study implemented distinct imaging protocols for each recruitment site. Infants being seen in the outpatient clinic were required to sit on their parents' laps, looking straight ahead. In contrast, infants recruited in the nursery (typically <48 hours postpartum) were imaged cradled in their parent's arms, with the infant's head extending past the parent's elbow. Given the nature of the algorithm being evaluated by this study, videos were retrospectively reviewed to ensure adequate lighting, a well-centered head looking forward, and the absence of similarly colored and/or textured objects against the contour of the infant's head. As seen in Supplemental Digital Content 1, poor lighting and background conflicts had significant deleterious effects on the ability of the algorithm to evaluate the head shape appropriately. (See figure, Supplemental Digital Content 1, which shows how data collected from the newborn nursery was often poorly illuminated with background conflicts, increasing the difficulty of obtaining an accurate cranial contour. <http://links.lww.com/PRSGO/C549>.) Thus, the dataset underwent a thorough data-cleaning stage, where images that did not meet the aforementioned criteria were removed. This was particularly relevant for infants recruited from the nursery, as the environment tended to be much darker, with varied lighting and significant shadows compared with the consistent overhead lighting in the outpatient clinic.

All remaining video recordings from subjects recruited in the nursery were reviewed retrospectively by an expert pediatric craniofacial surgeon (M.G.) to obtain a standard clinical diagnosis for all recordings in the dataset.

Measurement Algorithm

All video recordings were performed by a single member of the study team (A.W.) using an iPhone 7 Plus through a proprietary mobile application. The mobile application digitally overlays a standardized head outline over the phone's camera input to help standardize the

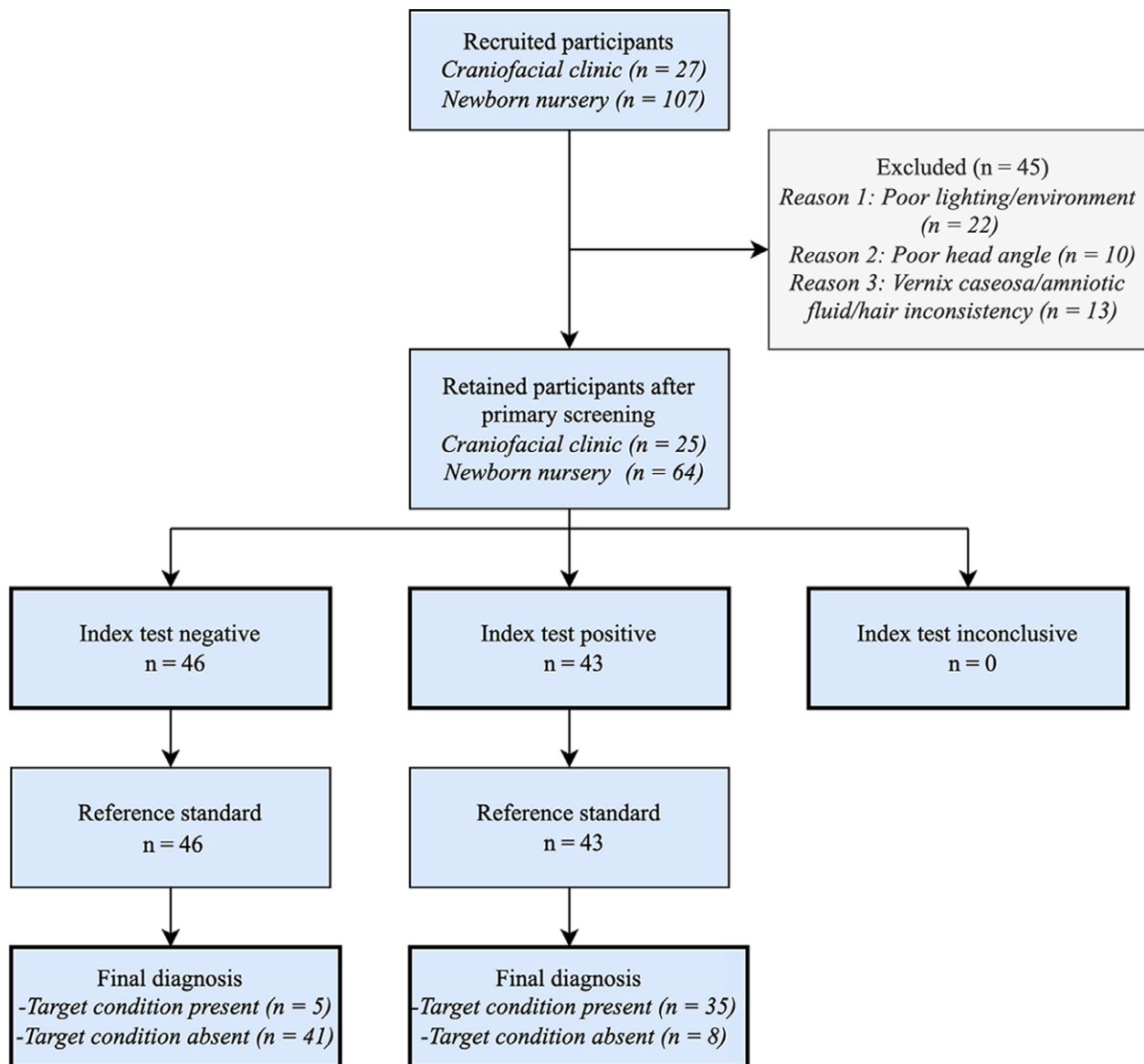


Fig. 1. Flow of participants through the study in accordance with the STARD.

recorded videos (Fig. 2). Once recorded, the short videos and all other clinical data were automatically encrypted and sent remotely to a cloud-based server. After data collection, the short videos were manually screened using Premiere Pro (Adobe Inc., Calif.) to identify the most representative, clear, centered frame of the head possible. This still image was then uploaded to the server for processing and analysis by the AI algorithm (Little Angel Medical Inc., QC, Canada). The AI algorithm leverages a combination of automatic edge detection (segmentation by active contouring) and a pre-trained convolutional neural network (a form of machine learning) to contour the infant's head automatically and infer anthropometric distances for calculation of cranial asymmetry indices (Fig. 3). Anthropometric cut-offs for plagiocephaly severity classification can be found in Figure 4. A successful AI diagnosis was achieved if the gross presence of positional

plagiocephaly and/or brachycephaly was appreciated in addition to the correct severity level when compared with standard clinical evaluation.

RESULTS

Demographics

A total of 89 infants [56 male infants (63%), 33 female infants (37%), mean age 2.37 months] were prospectively enrolled and retained in this study after obtaining signed informed consent from a parent/guardian. Recruitment occurred at two sites: the craniofacial surgery clinic [n = 25, 17 male infants (68%), eight female infants (32%), mean age 8.44 months] and the newborn nursery [n = 64, 29 male infants (45%), 25 female infants (39%), mean age 0 months]. From the craniofacial clinic recruitment

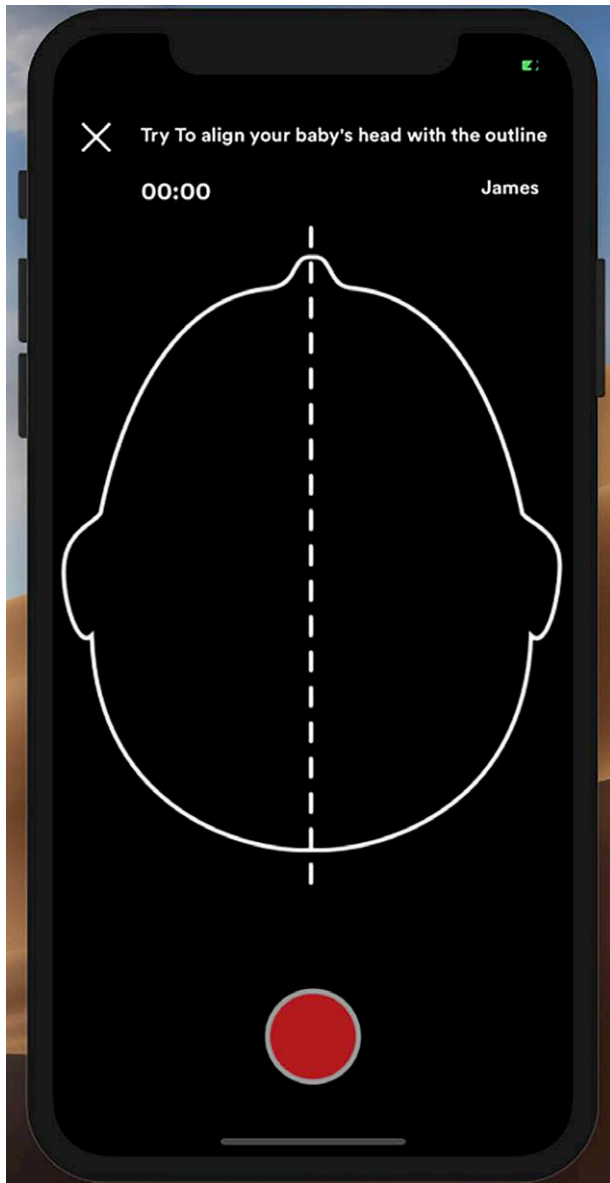


Fig. 2. Digital overlay of cranial outline to standardize and guide video recordings.

site, 23 patients were clinically diagnosed as having a form of plagiocephaly. The newborn nursery recruitment site yielded 17 patients who were retrospectively labeled as having a positional plagiocephaly-like head shape deformity and 47 patients with clinically normal head shapes. The distribution of plagiocephaly severity in the sample population can be found in [Figure 4](#).

AI Output

The AI algorithm, applied to the complete dataset, correctly classified positional plagiocephaly with an accuracy of 85.39% when compared with a standard clinical examination ([Fig. 5](#)). The OFF-1 score was 92.05%, with a sensitivity of 87.50% (95% CI, 75.94–98.42) and a specificity of 83.67% (95% CI, 72.35–94.99). The precision was

81.40%, with a positive predictive value of 81.40% and a negative predictive value of 89.13%. Likelihood ratios were 5.36 and 0.15 for the positive and negative ratio, respectively. Consequently, the diagnostic odds ratio was 35.875. The F1-score was 84.34%, and the Matthews correlation coefficient was 0.7047. Time required to implement the application in each clinical interaction (equal across both recruitment sites) was ~2 minutes.

Craniofacial clinic

Although representing a smaller sample size ($n = 25$), the data obtained from patient recruitment at the pediatric craniofacial surgery clinic constitute this study's best (most representative) data set. Ages ranged from 1 month to 10 months, with a median age of 6.98 months. Within this subgroup, AI performance increased measurably; OFF-1 was calculated to be 93.75% and sensitivity and specificity were 95.65% (95% CI, 87.32–103.99) and 100.00% (95% CI, 100–100) respectively. The F1-score was 0.9778 and the Matthews correlation coefficient was 0.7985.

Newborn Nursery

The nursery subset of our dataset required extensive cleaning due to the poor environmental conditions and young age of the children. As a result, the final newborn nursery dataset was composed of 64 images, down from 107. All infants were less than 48 hours old at the time of imaging, and many had not yet received full baths removing vernix caseosa/amniotic fluid from the child's head. OFF-1 was calculated to be 90.63% with sensitivity and specificity returning at 76.47% (95% CI, 56.31–96.63) and 82.98% (95% CI, 72.23–93.72), respectively. The F1-score was 0.6842, and the Matthews correlation coefficient was 0.5592.

DISCUSSION

The purpose of this study was to determine whether the implementation of a smartphone-based AI tool could result in clinically useful diagnoses of positional plagiocephaly in a pediatric population. The resultant prospective validation study of an AI-based mobile diagnostic tool obtained a sample size of 89 patients and achieved a diagnostic accuracy of 85.39%, with a sensitivity of 87.50% and a specificity of 83.67%. In addition, the application is easy to use and takes very little time to deploy in the clinical setting (~2 min/patient).

This work follows in the footsteps of previous studies implementing a variety of tools for the diagnosis of pediatric deformities. Callejas Pastor et al published a recent study using machine learning to diagnose positional plagiocephaly from two-dimensional images with an accuracy of 86.7%.¹⁴ Likewise, Agarwal et al, Bookland et al, and Geisler et al (among others) published studies evaluating AI algorithms applied to two-dimensional digital photographic images, with testing accuracies for synostotic deformities of 84.12%, 93.3%, and 90.6%, respectively.^{15–17} Importantly, all of the implementations above were trained and/or evaluated on a retrospectively curated

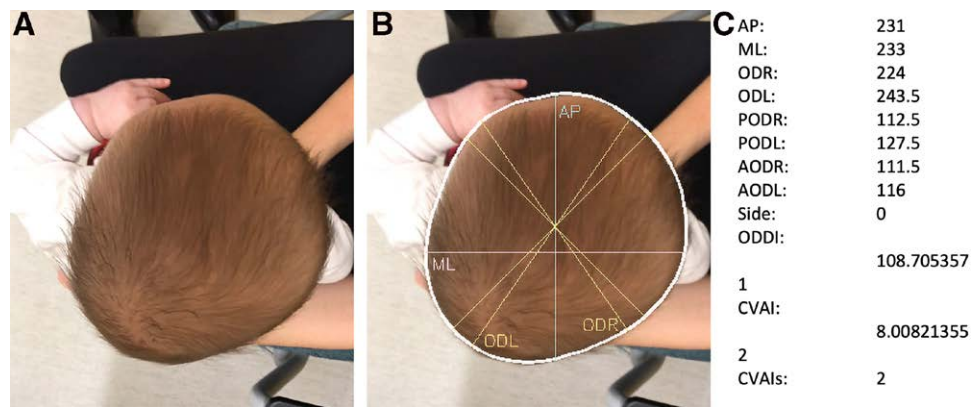


Fig. 3. Image analysis workflow for AI detection of positional plagiocephaly. Infant's head before (A) and after (B) automatic AI contouring of the cranium with defined cranial measurements (AP, ML, ODL, ODR), which are subsequently used to calculate craniometric indices for diagnostic purposes (C).

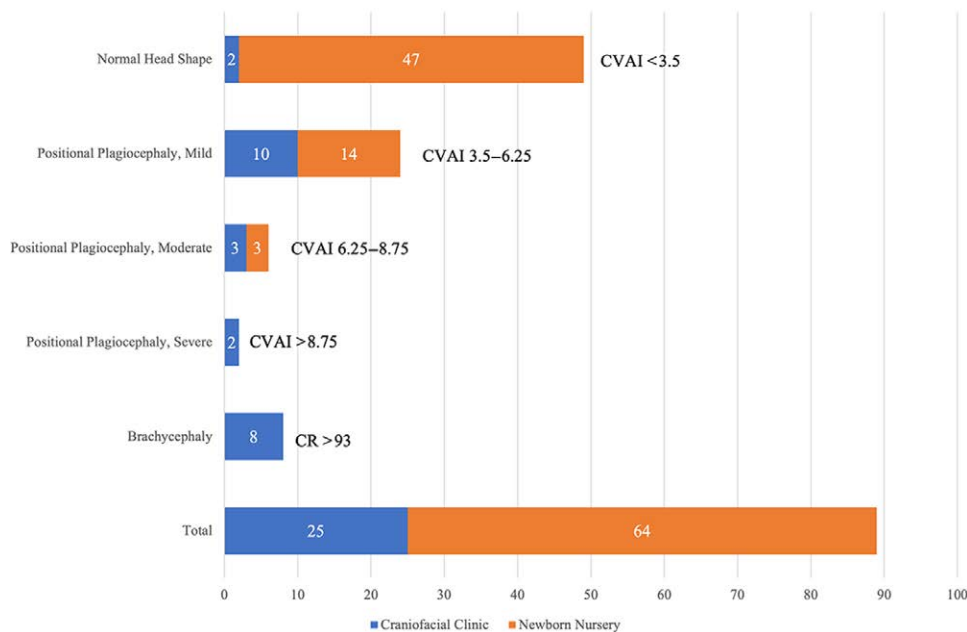


Fig. 4. Study sample characteristics stratified by diagnostic severity for craniofacial clinic and newborn nursery subgroups. CVAI, cranial vault asymmetry index; CR, cephalic ratio.

dataset and run on a desktop computer, limiting the translation of results to clinical practice. Furthermore, there exists intrinsic biases that are present in AI systems applied to retrospective datasets. Most importantly, the Clever-Hans type bias suggests that machine learning models may make predictions on spurious correlations in training data that do not exist in the real world, a significant barrier in the translation from pre-clinical to clinical diagnostic performance.^{18–20} Our results represent the diagnostic outcomes of an AI tool deployed prospectively, avoiding the Clever-Hans bias entirely.^{15–17}

Despite the inherent validation advantages of conducting a prospective study, there are notable challenges to be addressed. In this study, the authors faced significant difficulty deploying the AI tool in the newborn nursery thanks to contextual and environmental factors, leading

to a substantial loss of data (~40%). Given the delicate nature of recruiting families for participation in a study within 24–48 hours of a child's birth, certain accommodations were made. The most prominent was capturing head photos with poor and/or indirect lighting, which led to substantial shadows in the image and poor AI performance. (See **Supplemental Digital Content 1**, <http://links.lww.com/PRSGO/C549>.) Furthermore, infants had often not received their first bath which led to vernix caseosa/amniotic fluid creating abnormal edges within the contour of the skull. These challenges led us to conduct a thorough data cleaning where images with significant shadows or poor lighting were excluded to better evaluate AI performance. As a counterbalance to the poor conditions experienced in the newborn nursery, we performed a subgroup analysis to evaluate AI performance in both

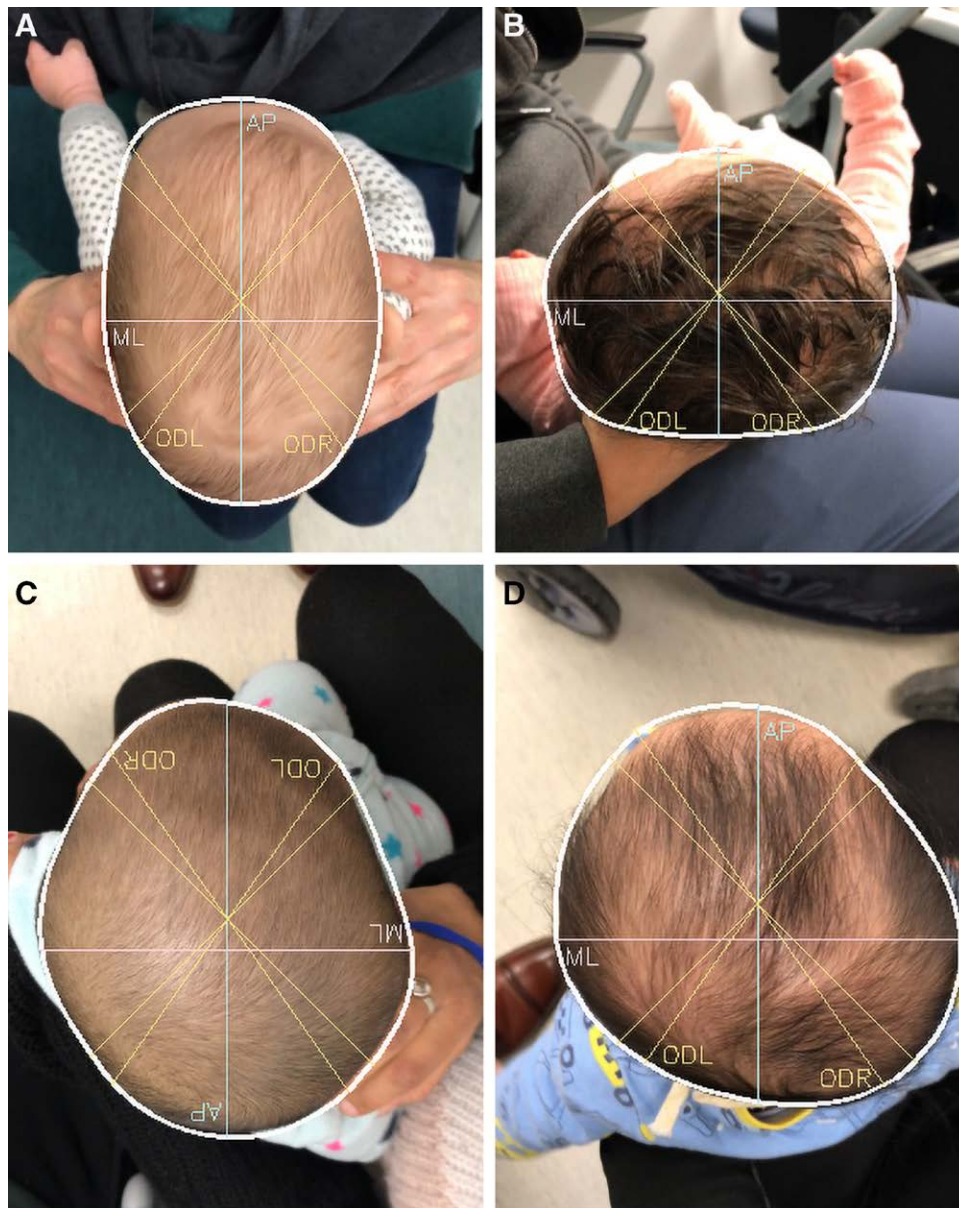


Fig. 5. Automatically applied AI contour is capable of contouring a broad range of head shapes. (A) Moderate scaphocephaly, (B) Bilateral coronal synostosis (severe brachycephaly), (C) Moderate left positional plagiocephaly, (D) Severe left positional plagiocephaly.

clinical environments (newborn nursery and craniofacial clinic). Despite the challenging environmental context, the nursery subgroup returned a sensitivity and specificity of 76.47% and 82.98%, respectively. The craniofacial clinic subgroup is formed of a more representative population for plagiocephaly diagnosis based on the demographics (age range 1–10 months, median age 6.98 months) and was much better controlled for lighting and environment, albeit with a much smaller sample size ($n = 25$). Although patients presenting to the clinic are more likely to have some degree of deformity than the general population, this sample included patients with normal head shapes that were simply referred for a second opinion. In this context, the craniofacial clinic subgroup saw substantially

stronger AI performance (sensitivity and specificity were 95.65% and 100.00%, respectively). Given the dichotomy between the two subgroups in infant age and environmental conditions for photography, the authors consider the overall AI accuracy of 85.39%, representing performance across a broad range of ages and conditions, to be a reasonable prediction of diagnostic strength. (See **Supplemental Digital Content 1**, <http://links.lww.com/PRSGO/C549>.)

Evaluation of any diagnostic tool is dependent on comparison to a reliable standard, which informs diagnostic performance. In this study, the AI tool was compared with the clinical judgment of an experienced pediatric craniofacial surgeon (M.G.). Clinical diagnosis is broadly recognized in the field as the standard diagnostic modality for

positional plagiocephaly; although radiographic options (such as CT) offer quantitative evaluation of head shape, they require exposure to radiation and/or anesthesia in a vulnerable population and are typically reserved for evaluation of a potential craniosynostosis.^{21–28}

The AI tool described in this study has several potential applications in the healthcare pathway. Given high patient volumes and short appointment times, pediatricians are faced with a significant challenge when monitoring infantile head shapes with no way to evaluate progression over time.²⁹ A significant advantage of an algorithmic approach to diagnosis in the primary/tertiary care setting is the ability to longitudinally track development in head shape beyond the head circumference, a common part of growth monitoring in infants. This promotes an ability to identify subtle trends in cranial development and can inform the need to refer for specialist consultation and management.

Additionally, handheld, easy-to-use diagnostic tools have a place in both parental monitoring and telemedicine applications. Parents play an essential role in the initial identification of positional plagiocephaly, often identifying cranial asymmetry and bringing it to the attention of the infant's pediatrician.¹¹ In this capacity, smart diagnostic applications that do not require specialized training have the potential to be powerful community-level screening tools. A longitudinal record of head development, recorded by parents, could help guide clinical decision-making for the treating physician. A demonstrated negative trend, for instance, could be indicative of a potential synostotic deformity, requiring consultation with pediatric craniofacial and/or neurosurgical teams. Conversely, a positive trend in cranial symmetry after at-home implementation of additional tummy time and physiotherapy may indicate a resolving plagiocephaly requiring monitoring but no additional consultation.^{11,29}

Recent events have highlighted an urgent need for improved modalities to provide adequate care remotely with telemedicine.^{30,31} Rizvi et al, alongside Marianayagam et al, have released studies evaluating the outcomes of virtual craniofacial clinics for the assessment of positional plagiocephaly based on standard digital images, concluding that virtual encounters resulted in comparable diagnostic accuracy.^{30,31} Implementation of an AI tool would further enhance that interaction by providing quantifiable metrics in support of a clinical diagnosis. As with other imaging-based diagnostic modalities, it will be important to correlate AI output with the clinical context when deciding on treatment initiation/specialist referral. Outside the context of a global health crisis, targeted improvement of telemedicine capability allows providers to deliver high-quality care to rural and small populations, a subset of patients that has historically been neglected.³²

Finally, the implementation of easy-to-use AI tools in the clinical environment gains importance in the context of longitudinal monitoring for synostotic plagiocephaly, particularly in cases of single-suture fusion where surgical intervention is either (a) not indicated or (b) delayed with continuous monitoring to optimize perioperative safety.³³ In these cases, the standard for clinical diagnosis is high-resolution three-dimensional computed tomography. Given

the movement to radiation and anesthesia stewardship in pediatric populations, implementing a nonradiographic modality without anesthesia in infants to longitudinally monitor head development (alongside serial ophthalmologic examinations) could be a valuable tool in the pocket of pediatricians and consulting specialists alike. Pathological changes in the growth pattern of the cranium could serve as an indication for follow-up and potential evaluation by three-dimensional computed tomography.³⁴

LIMITATIONS

Despite the promising results obtained from the smartphone-integrated AI algorithm in question, the study methodology used has limitations. Firstly, although being the largest of its kind in the literature, our sample size remains small for the validation of an AI tool; this result can be seen in the large spread of the 95% CI for the sensitivity and specificity metrics. Second, analysis of images obtained during recruitment at the newborn nursery imposed substantial challenges due to the infants' age and environmental context, as previously discussed. Consequently, we were forced to discard 40% of those images. Conversely, the craniofacial clinic (a more controlled environment) only required discarding of two images due to sudden movement of the infant that left the resulting still image significantly off-angle and, therefore, not representative of the cranial outline. Third, our study design did not include deployment of the AI algorithm in a primary care setting, which may underestimate the contribution of false negatives diagnosed in the community. Additionally, our design did not control for method of birth for those infants recruited from the newborn nursery (caesarean section versus vaginal delivery). Finally, all data were captured by a single member of the study team (A.W.) with a single capture of each infant's cranium, removing our ability to run intra- and inter-rater reliability analyses.

CONCLUSIONS

This study demonstrates the convincing performance of a smartphone-based AI-enabled diagnostic tool in one of the largest prospective validation studies in the craniofacial literature. The implementation of a tool, as described in this study, would give physicians and parents the ability to quantitatively, noninvasively, and affordably monitor the development of a child's head both at the point of care and longitudinally throughout the child's development. Such an implementation would assist primary caregivers in obtaining objective head shape measures which may inform earlier specialist consultation, ultimately promoting improved outcomes and lower costs via early diagnosis and treatment.

Mirko S. Gilardino, MD, MSc, FRCSC, FACS

Division of Plastic Surgery
McGill University Health Centre and
Montreal Children's Hospital
H.B. Williams Craniofacial & Cleft Surgery Unit
1001 Decarie Boulevard, B05.3310
Montreal, Quebec H4A 3J1
Canada

Email: mirko.gilardino.med@sss.gouv.qc.ca

DISCLOSURES

Ayden Watt received funding to support this research from Mitacs Inc. through the Mitacs Accelerate Internship. Dr. James Lee is the CEO of Little Angel Medical Inc., which developed the AI tool being evaluated in this study. Dr. Matthew Toews is the CTO of Little Angel Medical Inc. Little Angel Medical Inc. creates artificial intelligence-based child-monitoring tools. Little Angel Medical Inc. may potentially benefit financially from the research findings presented here. This study was supported by Mitacs INC.

REFERENCES

- Argenta L, David L, Thompson J. Clinical classification of positional plagiocephaly. *J Craniofac Surg*. 2004;15:368–372.
- Argenta LC, David LR, Wilson JA, et al. An increase in infant cranial deformity with supine sleeping position. *J Craniofac Surg*. 1996;7:5–11.
- Kane AA, Mitchell LE, Craven KP, et al. Observations on a recent increase in plagiocephaly without synostosis. *Pediatrics*. 1996;97(6 Pt 1):877–885.
- Feijen M, Franssen B, Vincken N, et al. Prevalence and consequences of positional plagiocephaly and brachycephaly. *J Craniofac Surg*. 2015;26:e770–e773.
- van Cruchten C, Feijen MMW, van der Hulst R. Demographics of positional plagiocephaly and brachycephaly; risk factors and treatment. *J Craniofac Surg*. 2021;32:2736–2740.
- Littlefield TR, Saba NM, Kelly KM. On the current incidence of deformational plagiocephaly: an estimation based on prospective registration at a single center. *Semin Pediatr Neurol*. 2004;11:301–304.
- Jung BK, Yun IS. Diagnosis and treatment of positional plagiocephaly. *Arch Craniofac Surg*. 2020;21:80–86.
- Di Rocco F, Ble V, Beuriat PA, et al. Prevalence and severity of positional plagiocephaly in children and adolescents. *Acta Neurochir (Wien)*. 2019;161:1095–1098.
- Martiniuk AL, Vujovich-Dunn C, Park M, et al. Plagiocephaly and developmental delay: a systematic review. *J Dev Behav Pediatr*. 2017;38:67–78.
- Kunz F, Schweitzer T, Große S, et al. Head orthosis therapy in positional plagiocephaly: longitudinal 3D-investigation of long-term outcomes, compared with untreated infants and with a control group. *Eur J Orthod*. 2018;41:29–37.
- Watt A, Alabdulkarim A, Lee J, Gilardino M. Practical review of the cost of diagnosis and management of positional plagiocephaly. *Plast Reconstr Surg Glob Open*. 2022;10:e4328.
- Watt A, Zammit D, Lee J, et al. Novel screening and monitoring techniques for deformational plagiocephaly: a systematic review. *Pediatrics*. 2022;149:e2021051736.
- Bossuyt PM, Reitsma JB, Bruns DE, et al; STARD Group. STARD 2015: an updated list of essential items for reporting diagnostic accuracy studies. *Bmj*. 2015;351:h5527.
- Callejas Pastor CA, Jung IY, Seo S, et al. Two-dimensional image-based screening tool for infants with positional cranial deformities: a machine learning approach. *Diagnostics (Basel)*. 2020;10:495.
- Bookland MJ, Ahn ES, Stoltz P, et al. Image processing and machine learning for telehealth craniosynostosis screening in newborns. *J Neurosurg*. 2021;27:581–588.
- Agarwal S, Hallac RR, Mishra R, et al. 2018 IEEE 8th International Conference on Computational Advances in Bio and Medical Sciences (iccabs). In: *Image Based Detection of Craniofacial Abnormalities Using Feature Extraction by Classical Convolutional Neural Network*. IEEE; 2018:1–6.
- Geisler EL, Agarwal S, Hallac RR, et al. A role for artificial intelligence in the classification of craniofacial anomalies. *J Craniofac Surg*. 2021;32:967–969.
- Lapuschkin S, Wäldchen S, Binder A, et al. Unmasking clever Hans predictors and assessing what machines really learn. *Nat Commun*. 2019;10:1096. et al.
- Maier-Hein L, Eisenmann M, Reinke A, et al. Why rankings of biomedical image analysis competitions should be interpreted with care. *Nat Commun*. 2018;9:5217.
- Reinke A, Tizabi MD, Eisenmann M, et al. Common pitfalls and recommendations for grand challenges in medical artificial intelligence. *European Urology Focus*. 2021;7:710–712.
- Purnell CA, Benz AW, Gosain AK. Assessment of head shape by craniofacial teams: structuring practice parameters to optimize efficiency. *J Craniofac Surg*. 2015;26:1808–1811.
- Miglioretti DL, Johnson E, Williams A, et al. The use of computed tomography in pediatrics and the associated radiation exposure and estimated cancer risk. *JAMA Pediatr*. 2013;167:700–707.
- Hall EJ. Lessons we have learned from our children: cancer risks from diagnostic radiology. *Pediatric Radiology*. 2002;32:700–706.
- Pogliani L, Zuccotti GV, Furlanetto M, et al. Cranial ultrasound is a reliable first step imaging in children with suspected craniosynostosis. *Childs Nerv Syst*. 2017;33:1545–1552.
- Eley KA, Watt-Smith SR, Sheerin F, et al. “Black Bone” MRI: a potential alternative to CT with three-dimensional reconstruction of the craniofacial skeleton in the diagnosis of craniosynostosis. *Eur Radiol*. 2014;24:2417–2426.
- Saarikko A, Mellanen E, Kuusela L, et al. Comparison of Black Bone MRI and 3D-CT in the preoperative evaluation of patients with craniosynostosis. *J Plast Reconstr Aesthet Surg*. 2020;73:723–731.
- Montoya JC, Eckel LJ, DeLone DR, et al. Low-dose CT for craniosynostosis: preserving diagnostic benefit with substantial radiation dose reduction. *Am J Neuroradiol*. 2017;38:672.
- Callahan MJ, MacDougall RD, Bixby SD, et al. Ionizing radiation from computed tomography versus anesthesia for magnetic resonance imaging in infants and children: patient safety considerations. *Pediatr Radiol*. 2018;48:21–30.
- Dias MS, Samson T, Rizk EB, et al. Identifying the misshapen head: craniosynostosis and related disorders. *Pediatrics*. 2020;146:e2020015511.
- Marianayagam NJ, Premaratne ID, Buontempo MM, et al. Outcomes of a virtual craniofacial clinic for assessing plagiocephaly during the COVID-19 pandemic. *J Neurosurg Pediatr*. 2021;28:497–501.
- Rizvi I, Fallah KN, Cepeda A, Jr, et al. Where are we headed? Diagnosing abnormal head shapes through virtual care visits. *J Craniofac Surg*. 2022;33:139–141.
- Haggerty T, Stephens HM, Peckens SA, et al. Telemedicine versus in-person primary care: impact on visit completion rate in a rural Appalachian population. *J Am Board Fam Med*. 2022;35:475–484.
- Xue AS, Buchanan EP, Hollier LHJ. Update in management of craniosynostosis. *Plast Reconstr Surg*. 2022;149:1209e–1223e.
- Florisson JMG, van Veelen M-LC, Bannink N, et al. Papilledema in isolated single-suture craniosynostosis: prevalence and predictive factors. *J Craniofac Surg*. 2010;21:20–24.