

ORIGINAL ARTICLE

Exploring the impact of hippocampal sclerosis on white matter tracts and memory in individuals with mesial temporal lobe epilepsy

Tamires A. Zanao^{1,2}  | Johanna Seitz-Holland¹ | Lauren J. O'Donnell³ |
 Fan Zhang^{1,3} | Yogesh Rathi¹ | Tátilla M. Lopes² |
 Luciana Ramalho Pimentel-Silva²  | Clarissa L. Yassuda² | Nikos Makris¹ |
 Martha E. Shenton^{1,3,4} | Sylvain Bouix⁵ | Amanda E. Lyall^{1,4} | Fernando Cendes² 

¹Psychiatry Neuroimaging Laboratory, Department of Psychiatry, Brigham and Women's Hospital, Harvard Medical School, Boston, Massachusetts, USA

²Neuroimaging Laboratory, School of Medical Sciences, University of Campinas, Campinas, São Paulo, Brazil

³Department of Radiology, Brigham and Women's Hospital, Harvard Medical School, Boston, Massachusetts, USA

⁴Department of Psychiatry, Massachusetts General Hospital, Harvard Medical School, Boston, Massachusetts, USA

⁵Département de génie logiciel et TI, École de technologie supérieure, Université du Québec, Montreal, Quebec, Canada

Correspondence

Fernando Cendes, Department of Neurology, University of Campinas, Rua Vital Brasil 251, Campinas, SP 13083-970, Brazil.
 Email: fcendes@unicamp.br

Funding information

Brain and Behavior Research Foundation, Grant/Award Number: 2019; Fundação de Amparo à Pesquisa do Estado de São Paulo, Grant/Award Number: 13/21056-4, 2013/07559-3, 2016/10433-0 and 2018/05393-4; National Alliance for Research on Schizophrenia and Depression, Grant/Award Number: Young Investigator Award; 5K24MH110807-05; National Institute of Mental Health, Grant/Award Number: 1 K01 MH115247-01A1

Abstract

Objective: To investigate how the presence/side of hippocampal sclerosis (HS) are related to the white matter structure of cingulum bundle (CB), arcuate fasciculus (AF), and inferior longitudinal fasciculus (ILF) in mesial temporal lobe epilepsy (MTLE).

Methods: We acquired diffusion-weighted magnetic resonance imaging (MRI) from 86 healthy and 71 individuals with MTLE (22 right-HS; right-HS, 34 left-HS; left-HS, and 15 nonlesional MTLE). We utilized two-tensor tractography and fiber clustering to compare fractional anisotropy (FA) of each side/tract between groups. Additionally, we examined the association between FA and nonverbal (WMS-R) and verbal (WMS-R, RAVLT codification) memory performance for MTLE individuals.

Results: White matter abnormalities depended on the side and presence of HS. The left-HS demonstrated widespread abnormalities for all tracts, the right-HS showed lower FA for ipsilateral tracts and the nonlesional MTLE group did not differ from healthy individuals. Results indicate no differences in verbal/nonverbal memory performance between the groups, but trend-level associations between higher FA of visual memory and the left CB ($r=0.286$, $P=0.018$), verbal memory (RAVLT) and -left CB ($r=0.335$, $P=0.005$), -right CB ($r=0.286$, $P=0.016$), and -left AF ($r=0.287$, $P=0.017$).

This is an open access article under the terms of the [Creative Commons Attribution-NonCommercial-NoDerivs](https://creativecommons.org/licenses/by-nc-nd/4.0/) License, which permits use and distribution in any medium, provided the original work is properly cited, the use is non-commercial and no modifications or adaptations are made.

© 2023 The Authors. *Epilepsia Open* published by Wiley Periodicals LLC on behalf of International League Against Epilepsy.

Significance: Our results highlight that the presence and side of HS are crucial to understand the pathophysiology of MTLE. Specifically, left-sided HS seems to be related to widespread bilateral white matter abnormalities. Future longitudinal studies should focus on developing diagnostic and treatment strategies dependent on HS's presence/side.

KEYWORDS

cognitive impairment, focal epilepsy, magnetic resonance imaging, white matter tracts

1 | INTRODUCTION

Individuals with epilepsy may demonstrate persistent and deteriorating memory performance.^{1,2} Even though seizures originate in gray matter, epilepsy is a whole-brain network disorder.³ The structural networks of the brain, which are made up of myelinated axons connecting gray matter areas, are central to the propagation of the electrical signals, which lead to epileptic seizures.⁴ Repeated seizures can be associated with microstructural white matter abnormalities.⁵ Furthermore, white matter alterations in individuals with epilepsy are related to memory performance,⁶ are a marker for pharmacoresistance,⁷ are pivotal for surgery planning,⁸ and can predict postsurgical cognitive deficits.^{9–11}

Temporal lobe epilepsy (TLE) is the most prevalent form of focal epilepsy in adults,¹² with mesial temporal lobe epilepsy (MTLE) being the most frequent subtype. While most individuals with MTLE have hippocampal sclerosis (HS),¹³ which can be diagnosed in vivo by magnetic resonance imaging (MRI),^{14,15} up to 20% have a nonlesional or negative MRI.¹³ Most current research investigating white matter abnormalities in epilepsy has utilized diffusion-weighted MRI (dMRI).⁴ These studies have typically reported the dMRI-derived measure known as fractional anisotropy (FA) as the primary measure of interest.^{4,10} FA is often interpreted to serve as a proxy for overall white matter health, with FA reductions generally indicating abnormalities in the structural organization of white matter.^{4,10} Indeed, several studies observed FA reductions in, for example, the cingulum bundle (CB), arcuate fasciculus (AF), and inferior longitudinal fasciculus (ILF), individuals with TLE.^{16–18}

Notably, the CB, AF, and ILF are all central for verbal and nonverbal memory performance, a domain often impaired in individuals with MTLE. These findings suggest a critical role of these three white matter bundles in the manifestation of TLE memory impairments, including verbal and nonverbal memory. Although episodic memory is also frequently impaired in individuals with MTLE, the association of the left hemisphere with verbal, and

Key points

- The location and extent of white matter (WM) abnormalities in mesial temporal lobe epilepsy (MTLE) are related to the presence and side of hippocampal sclerosis (HS).
- We observed widespread abnormalities in WM tracts related to memory performance for individuals with MTLE and left-HS.
- While individuals with MTLE and right-HS had abnormalities in the right hemisphere only, individuals without HS did not differ from healthy individuals.
- Our findings suggest that it is vital to study the presence and side of HS when trying to understand MTLE and its role in verbal and nonverbal memory performance and when identifying treatment targets.

right with nonverbal memory¹⁹ makes it appealing to explore memory relationships with white matter tracts left and right-sided.

Importantly, preliminary studies suggest that the presence of HS is related to the severity and extent of both white matter and cognitive abnormalities.^{9,10,20–25} Some studies have indicated that the side of HS is clinically meaningful, and the presence of left-HS is associated with more widespread white matter damage, more memory impairments, and a worse prognosis.^{19,26} On the contrary, others described bilaterally FA reductions.^{16,27} Little is known about nonlesional MTLE, suggesting the inconsistent results may be due to lateral and mesial mixed etiologies and underpowered studies. Demonstrated evidence indicates that each epilepsy syndrome has a different pattern of white matter alterations⁹ and a better characterization may help to understand further the pathophysiology, maybe leading to personalized treatment for each MTLE subgroup.

Therefore, it is currently unclear how the presence and side of HS relate to these findings and if white matter abnormalities in memory-related tracts are associated with cognitive deficits in MTLE, since direct comparison of diffusion measures and memory performance are still scarce.^{24,28,29}

The present study investigates white matter microstructure in individuals only with MTLE with the principal focus on whether the presence and side of HS yield a specific microstructural impact on white matter tracts associated with memory performance. We collected dMRI and cognitive data from healthy individuals, individuals with either a right or left unilateral HS (right-HS and left-HS group, respectively), and nonlesional MTLE of both lateralities (nonlesional MTLE group). Different from most previous studies, we utilized a machine-learning approach and fiber clustering methods³⁰ to extract and compare white matter FA of the CB, AF, and ILF between groups. Employing a method distinct from those used in most previous studies could enhance the validation of white matter microstructure changes in MTLE. Furthermore, these tracts are the primary focus considering their role in memory.^{6,31–34} Based on previous studies,^{4,10,23,25} we hypothesized that 1) the left-HS group will demonstrate more widespread white matter abnormalities than the right-HS group, and 2) white matter abnormalities will be less pronounced for the nonlesional MTLE group compared with the HS groups. Finally, we explored how the white matter microstructure of the CB, AF, and ILF is associated with verbal and nonverbal memory performance in individuals with MTLE.

2 | MATERIALS AND METHODS

The study was approved by the University of Campinas (UNICAMP) Ethical committee, and all participants signed informed consent in accordance with the Declaration of Helsinki. We recruited healthy controls from the UNICAMP community via advertisement and individuals with epilepsy at the outpatient Epilepsy Clinics at UNICAMP, Brazil. This is a retrospective study and the recruitment period occurred from January 2015 to July 2018.

All included subjects were Brazilian Portuguese native speakers between 21 and 70 years. Exclusion criteria for all participants were metal in their body, pregnancy, and any other health conditions that advise against MRI. Additional exclusion criteria for healthy controls were any past or present neurological or neuropsychiatric disorder diagnosed by trained neuropsychologists (TZ and TL) and neurologists (FC and YC). Last, we excluded healthy

controls if presenting with any structural brain abnormalities diagnosed by MRI.

All individuals with epilepsy presented with clinical and EEG features consistent with the diagnosis of MTLE according to the International League Against Epilepsy (ILAE) (<https://www.epilepsydiagnosis.org/seizure/temporal-over-view.html>³⁵). All individuals underwent serial diagnostic EEGs with at least 25 min of duration each, which were reviewed by a certified neurophysiologist (FC). We did not include individuals with polyspikes, bisynchronous discharges, discharges outside the temporal lobe regions, any neurologic comorbidity, or individuals submitted to brain surgery. As part of Epilepsy Clinics medical care, we employed an MRI epilepsy protocol following the ILAE recommendations for structural MRI in the care of patients with epilepsy on a 3 T scanner (Philips Achieva, Best, the Netherlands).¹⁵ MRI signs of HS were defined by visual analysis of hyperintense T2-weighted and Fluid-attenuated inversion recovery (FLAIR) signal and hippocampal atrophy on high-resolution 1 mm 3D T1-weighted and coronal 3 mm 2D T1-weighted inversion recovery images and confirmed by MRI volumetry as previously described.³⁶ Individuals were grouped into MTLE with MRI-negative of both lateralities (nonlesional MTLE), MTLE with unilateral HS on the right (right-HS), or left (left-HS). Patients with bilateral HS or other MRI lesions were not included.

Last, we recorded the response to pharmacotherapy of all individuals. Specifically, we inquired about the use of topiramate, as this antiseizure medication can affect cognitive abilities. Regarding the frequency of seizures, we considered seizures with impaired awareness self-report, categorizing individuals who were free or with two or fewer seizures during the previous year as *infrequent seizures* and those with three seizures or more during the previous year as *frequent seizures*.

2.1 | Image acquisition and processing

Images for research purposes were acquired on a 3 T Philips Achieva (Philips, Best, the Netherlands) at the Neuroimaging Laboratory – LNI, UNICAMP (Campinas, Brazil), with an eight-channel head coil. The diffusion-weighted magnetic resonance imaging protocol consisted of a spin-echo, single-shot, echo-planar imaging ($2 \times 2 \times 2 \text{ mm}^3$ acquiring voxel size, interpolated to $1 \times 1 \times 2 \text{ mm}^3$; reconstructed matrix 256×256 ; 70 slices; TE/TR 61/8500 ms; flip angle 90° ; 32 gradient directions; no averages; max b-factor = 1000 s/mm^2 ; six-min scan).

Diffusion-weighted images underwent preprocessing and quality control steps at the Psychiatry Neuroimaging

Laboratory (PNL), Brigham's and Women's Hospital, Harvard Medical School (Boston, USA), using the in-house pipeline (<https://github.com/pnlbwh/pnlutil/blob/master/pipeline/README.md>).

Briefly, diffusion images were axis-aligned, centered, and motion- and eddy-corrected by affine whole-brain registration of each gradient direction to the baseline B_0 using FLIRT (<https://fsl.fmrib.ox.ac.uk/fsl/fslwiki>). Brain masks (Slicer—software version 4.5, www.slicer.org)³⁷ were automatically generated, visually checked, and manually edited to exclude non-brain areas.

We utilized two-tensor Unscented Kalman Filter (UKF)³⁸ whole-brain tractography (<https://github.com/pnlbwh/ukftractography>), a multi-tensor filter method that uses tractography to drive the local fiber model estimation. Differently from other models that use independent estimation at each voxel, we performed tractography using Gaussian tensors to model the signal in a causal process, starting at a seed point and defining each new position along the fiber, based upon the previous position findings, and tracing the fibers to its termination. Compared with single-tensor model, multi-tensor model is especially relevant for identifying crossing-fibers and more complex diffusion patterns, allowing to find not only the main dominant pathway but also many of the anatomically known existing lateral pathways. The use of two Gaussian tensors enables the fiber estimation directly from the raw signal data without separate preprocessing. The two-tensor fiber model assumes ellipsoidal shape for tensors (preferred λ_1 direction, fixed weights). Equally weighted may limit flexibility, but adjust to fit the signal as a fully weighted model.³⁸ Considering the signal reconstruction is nonlinear and aiming to choose the most consistent direction, UKF was used to estimate the model parameters.³⁸

Previous studies demonstrated that UKF whole-brain tractography is highly sensitive and consistent.³⁹ Whole-brain tractography outputs were assessed using the semi-automated quality control tool in the *whitematteranalysis* software (<https://github.com/SlicerDMRI/whitematteranalysis>).³⁷ Next, we identified the white matter tracts for each subject using the White Matter Analysis (WMA) package, a robust machine-learning approach with high test–retest reproducibility.^{30,39} This method combines a well-established fiber clustering pipeline with a neuroanatomist-curated white matter atlas.^{39,40} Each participant's whole-brain tractography was registered to the atlas space. For detailed information, see Zekelman et al.⁴¹ Last, we performed visual and quantitative quality control of the parcellated tracts and extracted fractional anisotropy (FA) values for the CB, AF, and ILF.

2.2 | Neuropsychological assessment

Trained neuropsychologists conducted the cognitive evaluation of individuals, which included the *Wechsler Memory Scale-Revised* (WMS-R)⁴² (only Verbal Memory and Visual Memory indexes) and the *Key Auditory Verbal Learning Test* (RAVLT)⁴³ (only the codification subtest). The tests were selected to evaluate nonverbal memory (Visual Memory WMS-R), and verbal memory (Verbal Memory WMS-R and RAVLT codification) as these are the most consistently affected domains in individuals with MTLE.^{44,45} We did not perform cognitive assessments on healthy control participants.⁴³

2.3 | Statistical analyses

Statistical analyses were conducted using the Statistical Package for Social Sciences, version 26.

2.4 | FA analysis

We performed two one-way MANCOVAs to evaluate differences in the white matter tracts between the four groups (nonlesional MTLE, right-HS, left-HS, and healthy controls). We included the group as the independent variable, the FA values of CB, AF, and ILF as dependent variables, and sex and age as covariates. We utilized separate MANCOVAs for the left and right hemispheres to avoid multicollinearity. In the case of a significant group difference in the MANCOVA ($P < 0.025$, Bonferroni-corrected for two tests), we performed post hoc ANCOVAs for the three tracts. We then conducted pairwise comparisons only in the case of a significant group difference ($P < 0.017$, Bonferroni-corrected for three tracts). We applied this hierarchical approach of MANCOVAs, ANCOVAs, and post hoc comparisons to limit type I error.

2.5 | Neuropsychological analyses

Neuropsychological data were evaluated using three one-way ANCOVAs with the group as the independent variable (nonlesional MTLE, right-HS, and left-HS) and visual memory, verbal memory, and RAVLT codification as the dependent variable, respectively. Age, sex, and years of education were included as covariates, and a P value of < 0.017 was considered significant (Bonferroni-corrected for three tests). We conducted post hoc comparisons between the three single groups, only in the case of a significant group difference in the ANCOVA.

Last, we applied Pearson correlations to investigate the association between the FA of each tract and the three neuropsychological tests in individuals with epilepsy. We considered $P < 0.003$ significant (Bonferroni-corrected for six tracts and three neuropsychological tests).

3 | RESULTS

3.1 | Demographic and clinical information

We recruited 99 healthy controls and 92 individuals with MTLE. Thirteen healthy controls and 21 individuals with MTLE failed to meet the diffusion tensor imaging (DTI) quality control standards and were excluded from the analyses. Thus, our final sample consisted of 86 healthy controls and 71 MTLE individuals. The MTLE individuals were divided into nonlesional MTLE, right-HS, and left-HS, considering the presence and side of hippocampal sclerosis (Table 1). There was no significant difference among the groups for the duration of illness or use of topiramate.

3.2 | FA analysis

First, we conducted two MANCOVAs (left and right hemisphere) with the group as the independent variable and the FA values of CB, AF, and ILF as dependent variables. We observed a significant group effect for the left

($F_{9,441} = 3.004$, $\eta^2 = 0.058$, $P = 0.002$) and right hemisphere ($F_{9,438} = 5.872$, $\eta^2 = 0.108$, $P < 0.001$). Next, we conducted post hoc ANCOVAs for the three tracts of the left and right hemispheres separately. After multiple comparison corrections, we observed significant group effects for all tracts (Table 2). Last, we conducted multiple comparisons-corrected post hoc analyses to compare the single groups (Table 3, Figure 1). The tractography of CB, AF, and ILF is represented in Figure 2.

Healthy controls presented higher FA values than (a) individuals with left-HS for all tracts and (b) individuals with right-HS for CB and ILF. The nonlesional MTLE group showed higher FA values than (a) the left-HS group for all left-sided tracts and (b) the right-HS group for the right CB. We did not observe any significant group difference for any tract between (a) healthy controls and nonlesional MTLE individuals, nor (b) between the left-HS and right-HS groups.

3.3 | Neuropsychological analyses

There was no difference in the neuropsychological tests for any MTLE groups (Table S1). We, therefore, combined the MTLE groups and performed Pearson correlations to test for an association between the FA of each tract and the three neuropsychological tests. There were no significant correlations at the Bonferroni-corrected threshold for the six tracts and three tests ($P < 0.003$, Table S2), however, we observed a few correlations that exhibited trend-level significance. Specifically, we saw an association between the

TABLE 1 Clinical and demographic characteristics of healthy controls, nonlesional, right-HS, and left-HS.

	Healthy controls	Nonlesional	Right-HS	Left-HS	Statistical test
N	86	15	22	34	
Age	45.255 ± 10.667	48.466 ± 12.794	47.727 ± 12.589	44.558 ± 9.455	$F_{3,153} = 0.744$, $P = 0.528$
Sex (female/male)	54/32 63/37%	9/6 60/40%	15/7 68/32%	17/17 50/50%	Fisher's exact test $P = 0.512$
Handedness (right/left/both)	—	13/2/0 87/13/0%	21/1/0 95.45/4.55/%	32/1/1 94/3/3%	Fisher's exact test $P = 0.555$
Education (years)	12.450 ± 3.960	6.600 ± 3.738	7.430 ± 4.686	7.680 ± 4.262	$F_{3,100} = 11.245$, $P < 0.0001$
Epilepsy duration (years)	—	33.666 ± 13.350	30.136 ± 15.263	28.117 ± 13.377	$F_{2,68} = 0.824$, $P = 0.443$
Topiramate (yes/no)	—	26.7/ 73.3%	13.64/ 86.3%	23.53/ 76.47%	Fisher's exact test $P = 0.606$
Infrequent seizures/ frequent seizures	—	11/4	8/14	8/26	Fisher's exact test $P < 0.0001$

Note: Handedness measured by Edinburgh Handedness Inventory; education in years of school (regular Brazilian education system). Topiramate, percentage of topiramate use per group. Infrequent seizures, two or fewer seizures during the past year; frequent seizures, more than two seizures during the past year. Abbreviations: left-HS, individuals with MTLE and left hippocampal sclerosis; MTLE, mesial temporal lobe epilepsy; nonlesional, individuals with MTLE without hippocampal sclerosis; right-HS, individuals with MTLE and right hippocampal sclerosis.

Post hoc ANCOVA	Left FA	P values	Right FA	P values
CB	$F_{3,147} = 6.686$	0.001	$F_{3,146} = 12.075$	<0.001
AF	$F_{3,147} = 4.438$	0.005	$F_{3,146} = 11.177$	<0.001
ILF	$F_{3,147} = 6.155$	0.001	$F_{3,146} = 4.499$	<0.001

Abbreviations: AF, arcuate fasciculus; CB, cingulum bundle; FA, fractional anisotropy; ILF, inferior longitudinal fasciculus.

TABLE 2 Significant group differences for the six white matter tracts investigated in the current study.

TABLE 3 Fractional anisotropy differences between healthy controls, nonlesional, right-HS, and left-HS.

Comparison between single groups		Post hoc analyses (Bonferroni-corrected P values)					
		CB left	CB right	AF left	AF right	ILF left	ILF right
Controls	Nonlesional	+, 1.00	+, 1.00	−, 1.00	+, 0.237	+, 1.00	+, 1.00
	Right-HS	+, 0.369	+, 0.000	+, 0.479	+, 0.089	+, 0.852	+, 0.033
	Left-HS	+, 0.000	+, 0.001	+, 0.022	+, 0.000	+, 0.000	+, 0.022
Nonlesional	Right-HS	+, 0.602	+, 0.009	+, 0.207	+, 1	+, 1	+, 1.00
	Left-HS	+, 0.017	+, 0.354	+, 0.029	+, 0.394	+, 0.045	+, 1.00
Right-HS	Left-HS	+, 0.842	−, 0.479	+, 1.000	+, 0.247	+, 0.409	−, 1.00

Note: The “+” indicates that the fractional anisotropy value of the group in the first column is larger than the fractional anisotropy value of the group in the second column; the “−” indicates the opposite. The significant values are colored in gray.

Abbreviations: AF, arcuate fasciculus; CB, cingulum bundle; FA, fractional anisotropy; ILF, inferior longitudinal fasciculus.

left CB and visual memory ($r = 0.286$, $P = 0.018$); the left CB and RAVLT codification ($r = 0.335$, $P = 0.005$); the right CB and RAVLT codification ($r = 0.286$, $P = 0.016$) and the left AF and RAVLT codification ($r = 0.287$, $P = 0.017$). For each trend-level significant correlation, a better performance was associated with higher FA values in individuals with MTLE.

4 | DISCUSSION

This study investigated white matter microstructure in CB, AF, and ILF and the impact of the presence and side of HS in adults with MTLE. The main strengths of our paper are the use of a machine-learning approach with a different procedure for analyzing the white matter tracts, and the correlation of the findings with memory performance that has not been explored in most studies with DTI. We found a graded relationship dependent on the presence and side of HS for white matter abnormalities. As hypothesized, the left-HS group demonstrated more widespread white matter abnormalities than the right-HS group. While the left-HS group showed abnormal white matter for all three tracts in both hemispheres, the right-HS group experienced abnormal white matter for CB and ILF in only the right hemisphere. Our hypothesis was partially confirmed regarding the nonlesional MTLE group. We expected fewer abnormalities than the left-HS and right-HS groups but were surprised to find no abnormalities. The exploratory memory analysis

revealed no significant differences in verbal or nonverbal memory performance between the left-HS, right-HS, and nonlesional MTLE groups. In addition, we only observed trend-level significant associations between the white matter microstructure of the CB, AF, and ILF and memory performance.

4.1 | White matter abnormalities

Although previous studies have described white matter abnormalities as a core deficit of epilepsy, findings have been inconsistent regarding the extent and severity of white matter damage. Specifically, it is still an area of active debate whether white matter changes in individuals with epilepsy are constrained only to the same hemisphere of the epileptogenic zone (ipsilateral hemisphere)^{4,10} or found in both hemispheres.^{16,27} Also, as previously mentioned, studies have suggested that the side of HS is relevant for clinical purposes, and the left HS has been associated with a worse prognosis and more impairments in white matter and memory.^{19,26} However, previous results are somewhat inconsistent for specific tracts, such as CB, AF, and ILF. Given that a recent meta-analysis has shown that each epilepsy syndrome displays a unique pattern of white matter alterations, but without direct comparison with memory performance,⁹ we decided to further explore this question by investigating individuals with MTLE only, with unilateral HS (right-HS and left-HS) and without MRI signs of HS or other MRI abnormalities (nonlesional MTLE).

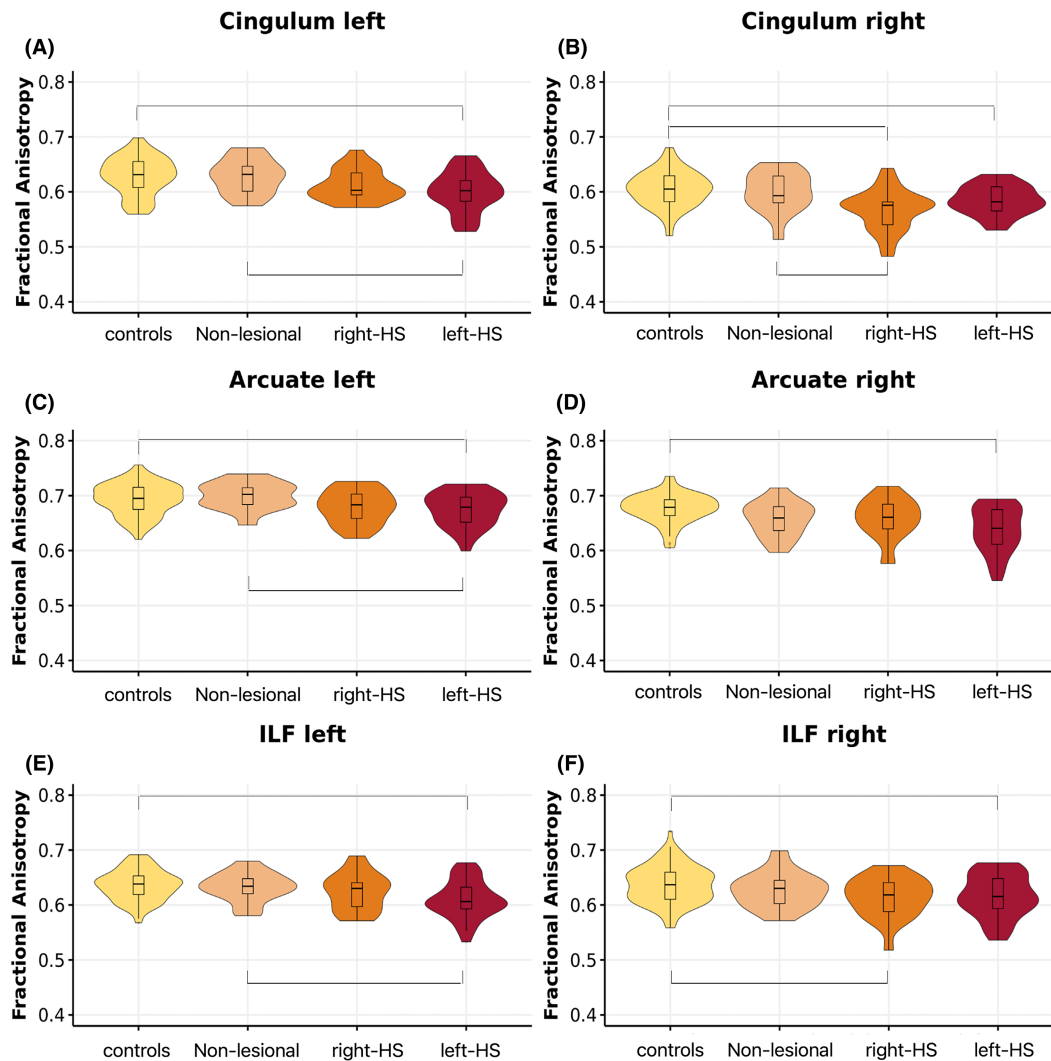


FIGURE 1 Group differences of fractional anisotropy (FA) between healthy controls, nonlesional, right-HS, and left-HS, for the left (A) and right (B) cingulum fasciculus, left (C) and right (D) arcuate fasciculus, and left (E) and right (F) inferior longitudinal fasciculus (ILF). Yellow, controls; light orange, MRI-negative; orange, right-HS; and pink-left-HS. Abbreviations: MTLE, mesial temporal lobe epilepsy; nonlesional, individuals with MTLE without hippocampal sclerosis; right-HS, individuals with MTLE and right hippocampal sclerosis; left-HS, individuals with MTLE and left hippocampal sclerosis.

Our findings align with our hypothesis that the left-HS group would be the most affected. Individuals with left-HS exhibited widespread bilateral white matter abnormalities in the CB, AF, and ILF compared to healthy individuals. However, the right-HS group displayed lower FA than controls for the ipsilateral (i.e., right-hemispheric) CB and ILF. While we expected that the nonlesional MTLE group would present with fewer FA reductions when compared to the other MTLE groups, we were surprised that the nonlesional group did not exhibit any abnormalities in the white matter tracts we investigated. Contrary to our study, few other authors have proposed that the absence of MRI signs of HS is associated with minor white matter damages instead of our observations of no differences.^{11,46} Our findings, however, agree with a smaller study by Concha and colleagues,¹⁸ which also showed that white matter

abnormalities were exclusive to MTLE patients with HS compared to those without HS for the CB. They further highlight how crucial it is to separate individuals into pathologically defined subgroups when trying to understand the complex pathophysiology of epilepsy.

Additionally, previous research reported that unilateral MTLE could be related to bilateral alterations of different regions, such as the CB.^{16,47} Focke and colleagues,¹⁶ who did not include a nonlesional group, revealed that unilateral MTLE was associated with a different pattern of FA reductions for left- and right-HS. In particular, these authors reported bilateral abnormalities of the AF for left-HS and unilateral abnormalities of the AF for right-HS. Our results partially overlap with these findings as we see bilateral AF abnormalities for the left-HS group but not for the right-HS group. It suggests that, at least in our sample, the

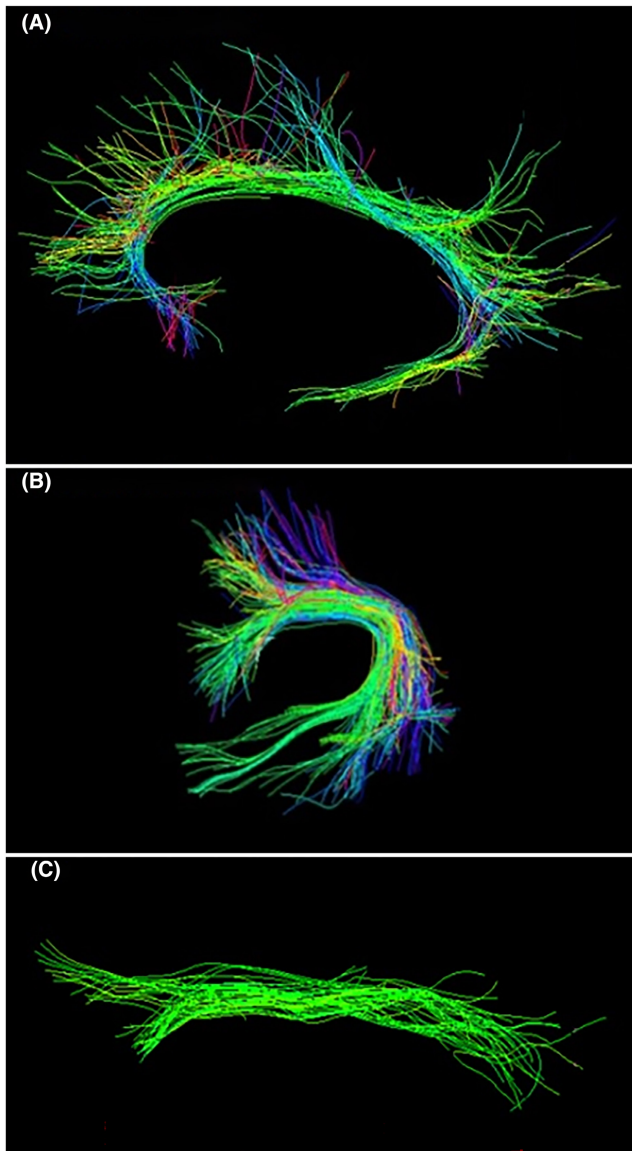


FIGURE 2 Tractography examples of A—cingulum bundle, B—arcuate fasciculus, and C—inferior longitudinal fasciculus. All images are left-sided. The colors represent the orientation of the fibers as follows: red, transverse fibers; green, anteroposterior fibers; and blue, craniocaudal fibers. Fibers with oblique orientation are colored with a combination of the primary colors. Figures are generated by Slicer—version 4.5.

AF might be more susceptible to damage associated with the left hippocampus and emphasizes that the right-HS may not affect all ipsilateral tracts with the same severity. Furthermore, our results agree with a few previous TLE studies^{25,28} that have reported bilateral FA reductions in the ILF for left-HS, while the right-HS group showed only ipsilateral abnormalities.

Interestingly, in a previous study,⁴⁸ we found a similar hierarchical pattern investigating the role of HS in the functional connectivity of the default mode network (DMN). We reported a possible compensatory re-organization of

the DMN for the right-HS and nonlesional MTLE groups. In contrast, the left-HS group did not show this pattern. We interpreted these findings to indicate an increasing connectivity disruption hierarchy, with the left-HS group having more disrupted connectivity than the right-HS and MTLE with negative MRI.⁴⁸ Future studies should investigate if resting-state functional connectivity is associated with structural white matter microstructure alterations in MTLE. These findings suggest considering the identification of HS as a potentially critical diagnostic measure. Nonlesional, right-, and left-HS seem to be associated with different functional and structural damages, resulting in distinct prognoses and possibly in different treatment strategies.

4.2 | Association between white matter microstructure and memory performance

Given that memory deficits are the most common cognitive impairments in individuals with MTLE⁴⁹ and verbal and nonverbal memory are considered side-related, we focused our cognitive analyses on verbal and nonverbal memory performance. Additionally, we selected the CB, AF, and ILF as relevant white matter tracts because all have previously been related to verbal and nonverbal memory performance. The CB and AF are linked to verbal^{31,50} and visuospatial memory.⁵¹ The AF connects Broca's and Wernicke's areas, and it is related to naming and verbal fluency tasks.^{28,50} The ILF is essential for cognitive flexibility, visual (specifically face), and language recognition.⁵⁰

Surprisingly, contrary to the aforementioned white matter findings, we observed no gradation differences between the three MTLE groups for verbal and nonverbal memory performance (as measured by the WMS-R and RAVLT). Some factors such as the absence of a control group comparison, low educational level of all three MTLE groups, the long duration of epilepsy (floor effect), uncontrolled onset, and different group sizes may have contributed to the absence of a gradual degree of memory loss. Although we did not investigate verbal and nonverbal memory performance in healthy controls, other studies have shown that WM microstructure is relevant for the adequate communication between gray matter areas associated with memory.^{52,53} Interestingly, a longitudinal study reported structural WM improvement⁵³ induced by working memory training in both young and older healthy adults, suggesting fiber tracts integrity is directly associated with verbal and nonverbal memory.

As we did not observe group differences for any of the cognitive tests, we conducted exploratory correlation analyses for the combined sample of all individuals with

MTLE. While no correlations remained significant after correction for multiple comparisons, we found trend-level correlations between the left CB and visual memory, the left and right CB and RAVLT performance, and the left AF and RAVLT performance. Although nonsignificant, better performance was associated with higher FA values for correlational associations, which is in accordance with another study.⁵¹ Thus, further longitudinal studies are needed to follow up on white matter abnormalities' role in memory performance in MTLE.

4.3 | Limitations and future directions

One limitation of the study is the unequal sample sizes between the patient groups, specifically the differences between the left-HS and right-HS groups, which could be attributed to the larger sample size of the left-HS group. Also, the nonsignificant result in the nonlesional MTLE group could be caused by its smaller sample size (15 vs. 86), and this should be explored further in larger studies. With a larger sample size, there is a higher likelihood of detecting significant differences between groups and obtaining more robust results. A smaller sample size, on the other hand, may limit the study's ability to identify subtle but meaningful differences.

We could not lateralize most patients in the nonlesional group using EEG, the resulting subgroups were too small for analyses; therefore, we consider left- and right-sided EEG nonlesional MTLE patients as a single group.

Furthermore, multiple testing can increase error type 1 and each of the three tracts was investigated on both right and left sides, we focused on the FA as it is the most used and well-established dMRI measure. Nevertheless, future studies should expand analyses to include mean, radial, and axial diffusivity and additional tracts to better understand the pathophysiology of epilepsy syndromes. Additionally, it will be essential to conduct longitudinal studies to examine the trajectory of structural and functional abnormalities, including memory performance, in individuals with MTLE. These studies may enlighten unanswered questions regarding the progress of the disease (i.e., if the presence of left-HS leads to more widespread white matter damage or alterations were already present from the beginning)^{19,26} and help to decide the best treatment options (i.e., the characteristics that indicate best surgery outcome; the best moment for surgery). Future investigations should also include neuropsychological evaluations of healthy controls and covariates for the age of onset of MTLE, type, and dosage of antiseizure medications not available in the present study. Also, memory is a complex higher-order function. The standard memory tests and the implications of these classical cognitive battery performances in real-life memory impairments have

been debated in the last decades.⁴⁹ As all neuropsychological tests have their own strengths and limitations, it may be important to consider using an additional test battery. More widespread white matter impairment in left-HS may be associated with the severity of the illness and should be further investigated. Additionally, a potential limitation includes the absence of registration of barbiturates, benzodiazepines, and other medications that may affect memory or other cognitive functions.

Another limitation is the significant difference in the self-reported seizures, with the left-HS presenting more impaired awareness seizures than the other MTLE groups. As there is a known association between the frequency of seizures and therapeutic efficacy, future longitudinal studies should focus on investigating if there is a causality between the presence and side of HS in MTLE and the frequency of seizures, or if the frequency of seizures themselves are associated with the white matter impairments. Also, we consider it difficult to accurately register the number of seizures as they are self-reported and individuals with MTLE may not recognize or remember their occurrences.

5 | CONCLUSIONS

In summary, we observed white matter abnormalities in individuals with epilepsy, dependent on the presence and side of HS. Individuals with left-HS presented widespread bilateral white matter abnormalities. Individuals with right-HS showed abnormalities only in the right hemisphere. The nonlesional MTLE group showed no white matter abnormalities compared with healthy individuals. Importantly, these graded abnormalities align with previous functional findings and highlight that nonlesional, right-HS, and left-HS should be studied when trying to understand the pathophysiology of MTLE. Last, we believe that future longitudinal studies are warranted to examine further the role of these specific structural pathologies in cognitive performance (e.g., memory) and clinical presentation.

AUTHOR CONTRIBUTIONS

TAZ, JS-H, LJO, and LR P-Silva: conceptualization, data acquisition, data curation, formal analysis, investigation, methodology, software, validation, visualization, writing—original draft preparation, writing—review and editing. FZ, YR, TML, and NM: methodology, data acquisition, writing—review and editing. MES, CLY, SB, LJO, AEL, and FC: conceptualization, data curation, investigation, methodology, project administration, supervision, writing—original draft preparation, writing—review and editing.

FUNDING INFORMATION

Study supported by FAPESP (São Paulo Research Foundation) operational grant 2013/07559-3. TAZ—FAPESP 2016/10433-0 and FAPESP 2018/05393-4. JS-H—Fellowship Award from Harvard Medical School Livingston and Young Investigator Grant sponsored by Mary and John Osterhaus and the Brain & Behavior Research Foundation. AEL—NIMH 1 K01 MH115247-01A1; Brain and Behavior Research Foundation: 2019 NARSAD Young Investigator Award; 5K24MH110807-05. LJO—P41EB015902 and R01MH074794 and R01MH119222. LRPS—FAPESP 13/21056-4.

CONFLICT OF INTEREST STATEMENT

The authors report no conflict of interest.

DATA AVAILABILITY STATEMENT

The data that support the findings of this study are available from the corresponding author upon reasonable request. The data are not publicly available as they include information that could compromise the privacy of the research participants.

EPILEPSIA ETHICAL PUBLICATION STATEMENT

We confirm that we have read the Journal's position on issues involved in ethical publication and affirm that this report is consistent with those guidelines.

ETHICS APPROVAL STATEMENT

The Ethics Committee of the University of Campinas approved this study.

PATIENT CONSENT STATEMENT

All patients and controls signed an informed consent approved by the Ethics Committee of the University of Campinas.

ORCID

Tamires A. Zanao  <https://orcid.org/0000-0001-7868-4332>

Luciana Ramalho Pimentel-Silva  <https://orcid.org/0000-0001-5045-9512>

Fernando Cendes  <https://orcid.org/0000-0001-9336-9568>

REFERENCES

- GBD 2016 Epilepsy Collaborators. Global, regional, and national burden of epilepsy, 1990–2016: a systematic analysis for the Global Burden of Disease Study 2016. *Lancet Neurol.* 2019;18(4):357–75.
- Bautista RED, Shapovalov D, Saada F, Pizzi MA. The societal integration of individuals with epilepsy: perspectives for the 21st century. *Epilepsy Behav.* 2014;35:42–9.
- Scharfman HE, Kanner AM, Friedman A, Blümcke I, Crocker CE, Cendes F, et al. Epilepsy as a network disorder (2): what can we learn from other network disorders such as dementia and schizophrenia, and what are the implications for translational research? *Epilepsy Behav.* 2018;78:302–12.
- Gross DW. Diffusion tensor imaging in temporal lobe epilepsy. *Epilepsia.* 2011;52(Suppl 4):32–4.
- Yu A, Li K, Li L, Shan B, Wang Y, Xue S. Whole-brain voxel-based morphometry of white matter in medial temporal lobe epilepsy. *Eur J Radiol.* 2008;65(1):86–90.
- Bell B, Lin JJ, Seidenberg M, Hermann B. The neurobiology of cognitive disorders in temporal lobe epilepsy. *Nat Rev Neurol.* 2011;7(3):154–64.
- Park KM, Cho KH, Lee HJ, Heo K, Lee BI, Kim SE. Predicting the antiepileptic drug response by brain connectivity in newly diagnosed focal epilepsy. *J Neurol.* 2020;267(4):1179–87.
- Bonilha L, Jensen JH, Baker N, Breedlove J, Nesland T, Lin JJ, et al. The brain connectome as a personalized biomarker of seizure outcomes after temporal lobectomy. *Neurology.* 2015;84(18):1846–53.
- Hatton SN, Huynh KH, Bonilha L, Abela E, Alhusaini S, Altmann A, et al. White matter abnormalities across different epilepsy syndromes in adults: an ENIGMA-Epilepsy study. *Brain.* 2020;143(8):2454–73.
- Otte WM, van Eijsden P, Sander JW, Duncan JS, Dijkhuizen RM, Braun KPI. A meta-analysis of white matter changes in temporal lobe epilepsy as studied with diffusion tensor imaging. *Epilepsia.* 2012;53(4):659–67.
- Labate A, Cherubini A, Tripepi G, Mumoli L, Ferlazzo E, Aguglia U, et al. White matter abnormalities differentiate severe from benign temporal lobe epilepsy. *Epilepsia.* 2015;56(7):1109–16.
- Fuerst D, Shah J, Shah A, Watson C. Hippocampal sclerosis is a progressive disorder: a longitudinal volumetric MRI study. *Ann Neurol.* 2003;53(3):413–6.
- Cendes F, Sakamoto AC, Spreafico R, Bingaman W, Becker AJ. Epilepsies associated with hippocampal sclerosis. *Acta Neuropathol.* 2014;128(1):21–37.
- Blümcke I, Thom M, Aronica E, Armstrong DD, Bartolomei F, Bernardoni A, et al. International consensus classification of hippocampal sclerosis in temporal lobe epilepsy: a task force report from the ILAE Commission on Diagnostic Methods. *Epilepsia.* 2013;54(7):1315–29.
- Bernasconi A, Cendes F, Theodore WH, Gill RS, Koepp MJ, Hogan RE, et al. Recommendations for the use of structural magnetic resonance imaging in the care of patients with epilepsy: a consensus report from the international league against epilepsy neuroimaging task force. *Epilepsia.* 2019;60(6):1054–68.
- Focke NK, Yogarajah M, Bonelli SB, Bartlett PA, Symms MR, Duncan JS. Voxel-based diffusion tensor imaging in patients with mesial temporal lobe epilepsy and hippocampal sclerosis. *Neuroimage.* 2008;40(2):728–37.
- Govindan RM, Makki MI, Sundaram SK, Juhász C, Chugani HT. Diffusion tensor analysis of temporal and extra-temporal lobe tracts in temporal lobe epilepsy. *Epilepsy Res.* 2008;80(1):30–41.
- Concha L, Beaulieu C, Collins DL, Gross DW. White-matter diffusion abnormalities in temporal-lobe epilepsy with and without mesial temporal sclerosis. *J Neurol Neurosurg Psychiatry.* 2009;80(3):312–9.

19. Fernandes DA, Yasuda CL, Lopes TM, Enrico G, Alessio A, Tedeschi H, et al. Long-term postoperative atrophy of contralateral hippocampus and cognitive function in unilateral refractory MTLE with unilateral hippocampal sclerosis. *Epilepsy Behav.* 2014;36:108–14.
20. Muhlhofer W, Tan YL, Mueller SG, Knowlton R. MRI-negative temporal lobe epilepsy—What do we know? *Epilepsia.* 2017;58(5):727–42.
21. Whelan CD, Haaker JG, Sisodiya SM. Structural brain abnormalities in the common epilepsies assessed in a worldwide ENIGMA study. Oxford: Universität; 2018.
22. Pustina D, Doucet G, Sperling M, Sharan A, Tracy J. Increased microstructural white matter correlations in left, but not right, temporal lobe epilepsy. *Hum Brain Mapp.* 2015;36(1):85–98.
23. Kemmotsu N, Girard HM, Bernhardt BC, Bonilha L, Lin JJ, Tecoma ES, et al. MRI analysis in temporal lobe epilepsy: cortical thinning and white matter disruptions are related to side of seizure onset. *Epilepsia.* 2011;52(12):2257–66.
24. Ahmadi ME, Hagler DJ Jr, McDonald CR, Tecoma ES, Iragui VJ, Dale AM, et al. Side matters: diffusion tensor imaging tractography in left and right temporal lobe epilepsy. *AJNR Am J Neuroradiol.* 2009;30(9):1740–7.
25. Zhao X, Zhou ZQ, Xiong Y, Chen X, Xu K, Li J, et al. Reduced interhemispheric white matter asymmetries in medial temporal lobe epilepsy with hippocampal sclerosis. *Front Neurol.* 2019;24(10):394.
26. Helmstaedter C, Elger CE. Chronic temporal lobe epilepsy: a neurodevelopmental or progressively dementing disease? *Brain.* 2009;132(Pt 10):2822–30.
27. Riley JD, Franklin DL, Choi V, Kim RC, Binder DK, Cramer SC, et al. Altered white matter integrity in temporal lobe epilepsy: association with cognitive and clinical profiles. *Epilepsia.* 2010;51(4):536–45.
28. Besson P, Dinkelacker V, Valabregue R, Thivard L, Leclerc X, Baulac M, et al. Structural connectivity differences in left and right temporal lobe epilepsy. *Neuroimage.* 2014;100:135–44.
29. Sanjari Moghaddam H, Rahmani F, Aarabi MH, Nazem-Zadeh MR, Davoodi-Bojd E, Soltanian-Zadeh H. White matter microstructural differences between right and left mesial temporal lobe epilepsy. *Acta Neurol Belg.* 2020;120(6):1323–31.
30. Zhang F, Wu Y, Norton I, Rathi Y, Golby AJ, O'Donnell LJ. Test-retest reproducibility of white matter parcellation using diffusion MRI tractography fiber clustering. *Hum Brain Mapp.* 2019;40(10):3041–57.
31. Bubb EJ, Metzler-Baddeley C, Aggleton JP. The cingulum bundle: anatomy, function, and dysfunction. *Neurosci Biobehav Rev.* 2018;92:104–27.
32. Herbet G, Zemmoura I, Duffau H. Functional anatomy of the inferior longitudinal fasciculus: from historical reports to current hypotheses. *Front Neuroanat.* 2018;12:77.
33. Hodgetts CJ, Postans M, Warne N, Varnava A, Lawrence AD, Graham KS. Distinct contributions of the fornix and inferior longitudinal fasciculus to episodic and semantic autobiographical memory [Internet]. *Cortex.* 2017;94:1–14. <https://doi.org/10.1016/j.cortex.2017.05.010>
34. Wang T, Hu Y, Wang D, Liu J, Sun J, Wei C, et al. Arcuate fasciculus subsegment impairments distinctly associated with memory and language deficits in acute mild traumatic brain injury patients. *J Neurotrauma.* 2021;38(23):3279–87.
35. Berg AT, Berkovic SF, Brodie MJ, Buchhalter J, Cross JH, van Emde BW, et al. Revised terminology and concepts for organization of seizures and epilepsies: report of the ILAE Commission on Classification and Terminology, 2005–2009. *Epilepsia.* 2010;51(4):676–85.
36. Coan AC, Kubota B, Bergo FPG, Campos BM, Cendes F. 3T MRI quantification of hippocampal volume and signal in mesial temporal lobe epilepsy improves detection of hippocampal sclerosis. *AJNR Am J Neuroradiol.* 2014;35(1):77–83.
37. Zhang F, Noh T, Juvekar P, Frisken SF, Rigolo L, Norton I, et al. SlicerDMRI: diffusion MRI and Tractography research software for brain cancer surgery planning and visualization. *JCO Clin Cancer Inform.* 2020;4:299–309.
38. Malcolm JG, Shenton ME, Rathi Y. Filtered multitensor tractography. *IEEE Trans Med Imaging.* 2010;29(9):1664–75.
39. Zhang F, Wu Y, Norton I, Rigolo L, Rathi Y, Makris N, et al. An anatomically curated fiber clustering white matter atlas for consistent white matter tract parcellation across the lifespan. *Neuroimage.* 2018;179:429–47.
40. O'Donnell LJ, Wells WM 3rd, Golby AJ, Westin CF. Unbiased groupwise registration of white matter tractography. *Med Image Comput Comput Assist Interv.* 2012;15(Pt 3):123–30.
41. Zekelman LR, Zhang F, Makris N, He J, Chen Y, Xue T, et al. White matter association tracts underlying language and theory of mind: an investigation of 809 brains from the human connectome project. *Neuroimage.* 2022;246:118739.
42. Wechsler D. Wechsler memory scale - revised. Psychological Corporation. San Antonio: Psychological Corporation; 1987. p. 150.
43. Lezak MD, Howieson DB, Bigler ED, Tranel D. Neuropsychological assessment. New York: OUP USA; 2012. p. 1161.
44. Zeman A, Kapur N, Jones-Gotman M. Epilepsy and memory. Oxford: OUP Oxford; 2012. p. 464.
45. Milner B, Petrides M, Smith ML. Frontal lobes and the temporal organization of memory. *Hum Neurobiol.* 1985;4(3):137–42.
46. Labate A, Aguglia U, Tripepi G, Mumoli L, Ferlazzo E, Baggetta R, et al. Long-term outcome of mild mesial temporal lobe epilepsy: a prospective longitudinal cohort study. *Neurology.* 2016;86(20):1904–10.
47. Concha L, Beaulieu C, Gross DW. Bilateral limbic diffusion abnormalities in unilateral temporal lobe epilepsy. *Ann Neurol.* 2005;57(2):188–96.
48. Zanão TA, Lopes TM, de Campos BM, Yasuda CL, Cendes F. Patterns of default mode network in temporal lobe epilepsy with and without hippocampal sclerosis. *Epilepsy Behav.* 2021;121(Pt B):106523.
49. Saling MM. Verbal memory in mesial temporal lobe epilepsy: beyond material specificity. *Brain.* 2009;132(Pt 3):570–82.
50. McDonald CR, Ahmadi ME, Hagler DJ, Tecoma ES, Iragui VJ, Gharapetian L, et al. Diffusion tensor imaging correlates of memory and language impairments in temporal lobe epilepsy. *Neurology.* 2008;71(23):1869–76.
51. Leyden KM, Kucukboyaci NE, Puckett OK, Lee D, Loi RQ, Paul B, et al. What does diffusion tensor imaging (DTI) tell us about cognitive networks in temporal lobe epilepsy? *Quant Imaging Med Surg.* 2015;5(2):247–63.
52. Nagy Z, Westerberg H, Klingberg T. Maturation of white matter is associated with the development of cognitive functions during childhood. *J Cogn Neurosci.* 2004;16(7):1227–33.

53. Dziemian S, Appenzeller S, von Bastian CC, Jäncke L, Langer N. Working memory training effects on white matter integrity in young and older adults. *Front Hum Neurosci*. 2021;15:605213.

SUPPORTING INFORMATION

Additional supporting information can be found online in the Supporting Information section at the end of this article.

How to cite this article: Zanao TA, Seitz-Holland J, O'Donnell LJ, Zhang F, Rathi Y, Lopes TM, et al. Exploring the impact of hippocampal sclerosis on white matter tracts and memory in individuals with mesial temporal lobe epilepsy. *Epilepsia Open*. 2023;8:1111–1122. <https://doi.org/10.1002/epi4.12793>